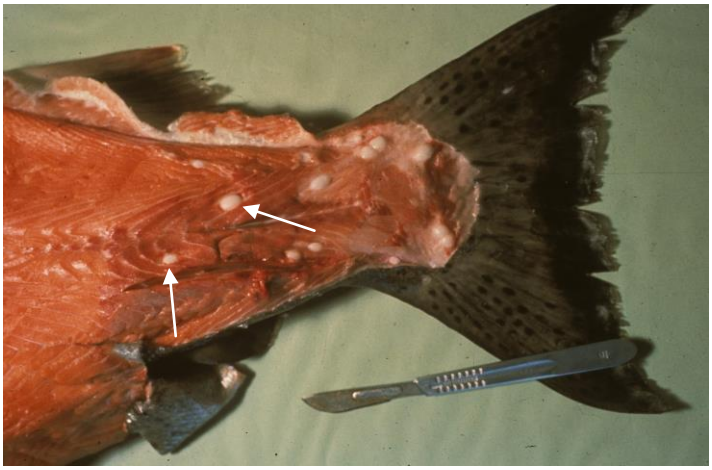

Figure 52

Henneguya zschokkei. White cysts (arrows) in muscle of an adult Chinook salmon.

(Courtesy of H. Wolf)

Figure 53

H. zschokkei spores in a sectioned cyst from a yearling rainbow trout body muscle. Note paired polar capsules (arrows).

M-G G stain. X640.

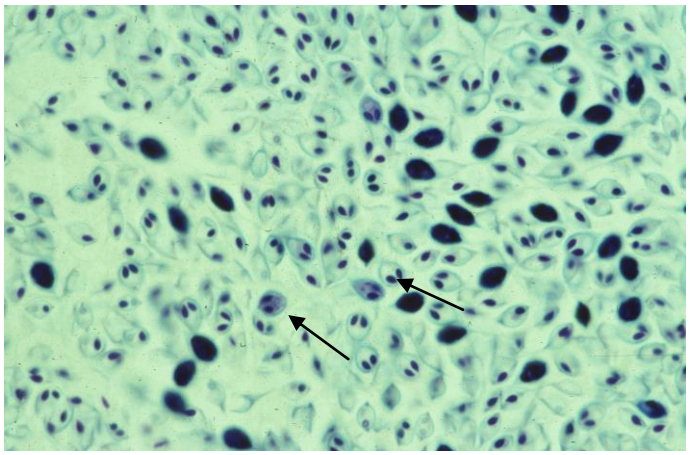

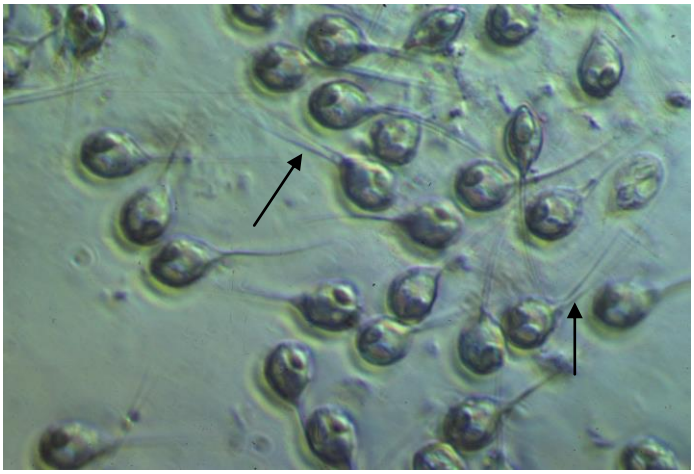

Figure 54

Henneguya sp. spores from a cyst in muscle of a rainbow trout. Note the 2 polar capsules at the anterior end and the long paired hair-like processes extending from the posterior end of each spore (arrows).

Wet mount. DIC. X1100.