Plate 2

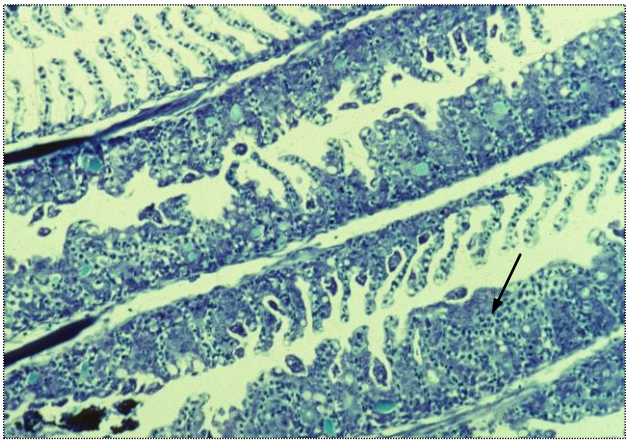

Figure 4

T. hoffmani in gill section of a fingerling Chinook salmon. Note hyperplastic lamellar epithelium (arrow).

M-G G stain. X200.

Figure 5

T. hoffmani (arrow). Higher magnification of Fig. 4. Note hypertrophy and hyperplasia of the lamellar epithelium.

M-G G stain. X500.

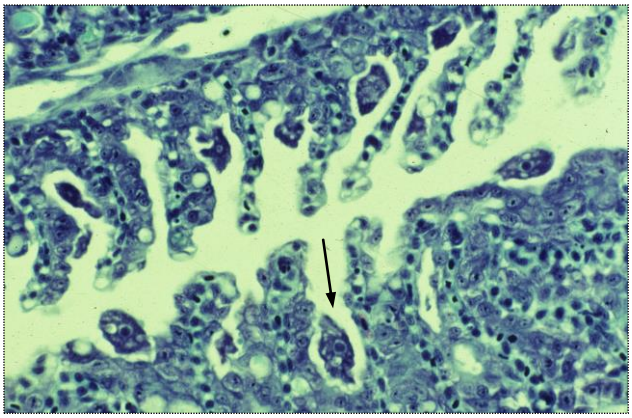

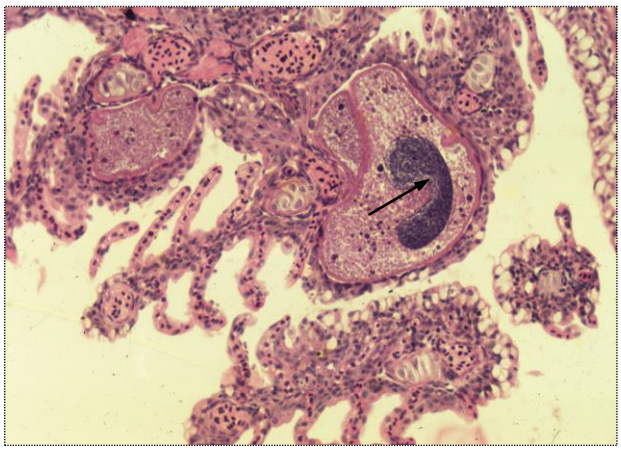

Figure 6

Icthyophthirius multifiliis in the gill of a fingerling rainbow trout. Note the characteristic horseshoe-shaped mucleus (arrow).

H&E stain. X250.